

Use of 3D Multislice CT in the Study of a Fetus with Cyclopia

Utilización de TC Multicorte 3D en el Estudio de un Feto con Ciclopia

*Harry Pachajoa; **Luis Eduardo Vejarano & ***Carolina Isaza

PACHAJOA, H.; VEJARANO, L. E. & ISAZA, C. Use of 3D multislice CT in the study of a fetus with cyclopia. *Int. J. Morphol.*, 30(1):88-93, 2012.

SUMMARY: Cyclopia is a rare congenital malformation incompatible with life; it is characterized by the presence of a single eye in the center position, secondary to alobar holoprosencephaly. Cyclopia etiology is heterogeneous, with a prevalence of 1.05 in 100,000 births. We report a case of cyclopia with sinofthalmía in a fetus of 21 weeks where they use 3D multislice computed tomography as a complementary study.

KEY WORDS: Cyclopia; Holoprosencephaly; Computer tomography; Prenatal diagnosis.

INTRODUCTION

Cyclopia is a major congenital malformation, resulted from a sequence that starts with a defect in the division of the anterior brain leading to alobar holoprosencephaly and fusion of the eyes characterized by the presence of a central eye as a result of the merger of the two eyes and alobar holoprosencephaly, It is characterized by a single orbit that contains the structure of the eye, and it can be both a cylindrical structure called proboscis, and is usually located above the orbit (Liu *et al.*, 1997; Bendavid *et al.*, 2010).

The prevalence of this malformation is estimated at 1.05 per 100,000 births, including stillbirths, being more common in female fetuses (Källén *et al.*, 1992).

The most severe forms of holoprosencephaly result in severe facial deformities. These anomalies include cyclopia, etmocefalia, central cleft lip and cebocephaly. Cyclopia is the most severe phenotype of holoprosencephaly, which can be divided into alobar, which includes cyclopia, in semilobar and lobar (Table I) (Liu *et al.*). We report a case of holoprosencephaly which includes the 3D multislice computed tomography as a complementary study.

CASE REPORT

We present a patient with cyclopia, son of a no consanguineous parents, 35-year old mother. The product of a fourth pregnancy, of a mother with a history of four pregnancies without complications. The mother refers to an institution for fetal death with a prenatal diagnosis on the second trimester of intrauterine growth restriction, alobar holoprosencephaly and cyclopia.

At birth there is a male fetus of 21 weeks gestation, weight 320g, length coccyx skull of 17cm, length skull heel of 24cm, heel length is 3.5cm, the umbilical cord segment measured 11.3x0.8cm. Physical examination found cyclopia with sinophthalmia (Figs. 1 and 2).

Further studies, presented karyotype which was taken at 20 weeks showing a normal chromosome complement (46, XY). After birth 3D multislice computerized tomography realized, indicating alobar holoprosencephaly, a fusion of thalami and corpus callosum agenesis.

Parents authorize the autopsy where alobar holoprosencephaly is found with hemispheres connected

* Profesor y Jefe del Departamento de Ciencias Básicas Médicas. Fundación Clínica Valle del Lili. Facultad de Ciencias de la Salud, Universidad Icesi, Cali, Colombia.

** Patólogo, Clínica Comfenalco, Cali, Colombia.

*** Profesora Facultad de Salud, Universidad del Valle, Cali, Colombia.

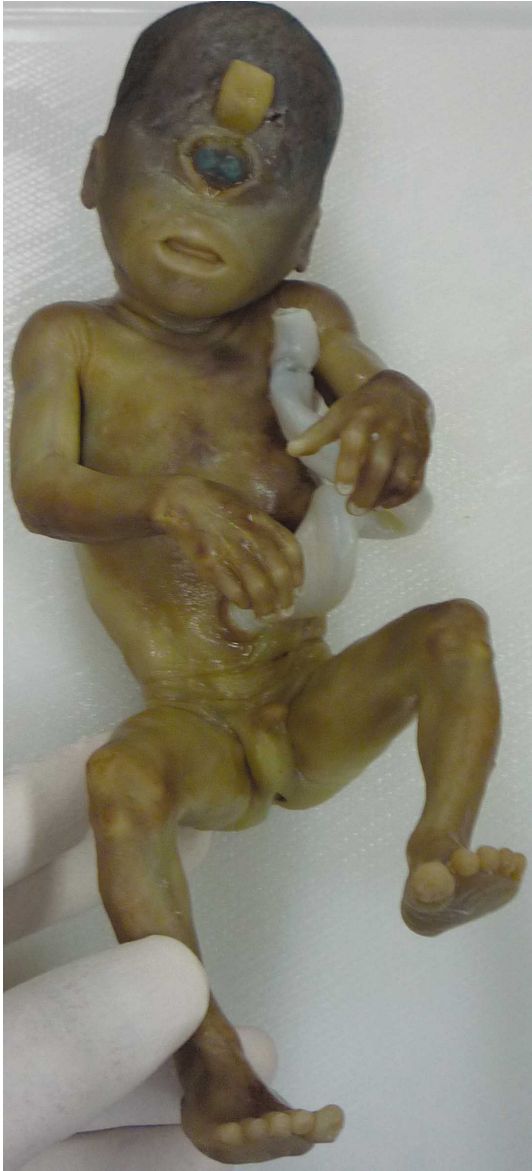

Fig. 1. General view of 21-week fetus with cyclopia and synophthalmia.

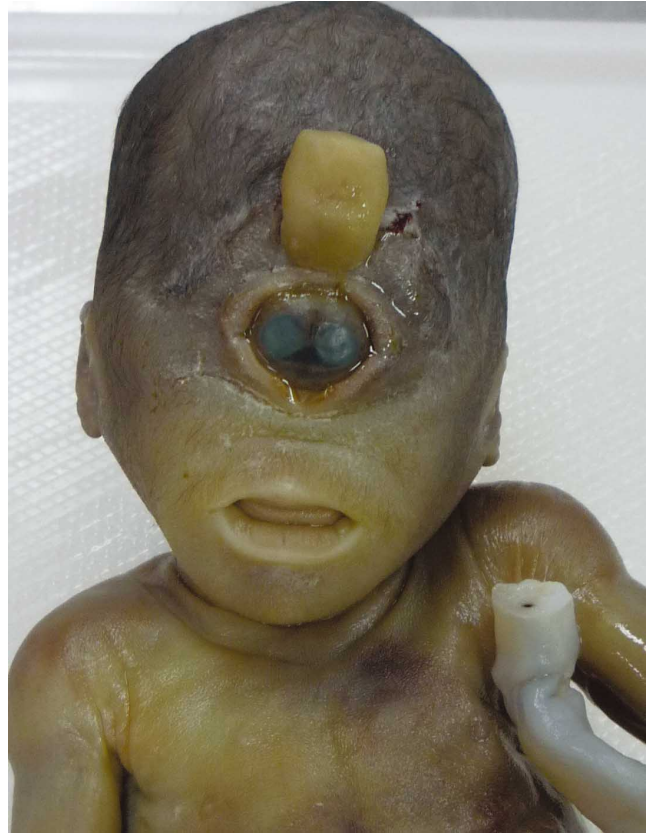

Fig. 2. Fetus with cyclopia and synophthalmia, note the presence of two irises in one orbit.

by a bridge of cortical tissue with agenesis of the corpus callosum, the evidence a great single ventricular occupies 40 percent of the brain, a single fusion brain hemisphere and a court shows a large single ventricular cavity drain extra fluids, brain structure occupies a third of the cranial cavity, the hemispheres are seen fused with poor differentiation of convolutions with cerebellar heterotopias and brain stem, brain measures 2.5 x 2 inches and fused thalami.

Table I. Classification of holoprosencephaly.

Holoprosencephaly types	Characteristics
Alobar	One lobe of the brain, prosencephalon, with a single ventricle and fused thalami.
Semilobar	Two hemispheres partial separated by a posterior cleft, and united previously observed in a horseshoe shape with a single ventricle and fused thalami.
Lobar	Two hemispheres, two ventricles, two thalami but with midline defects and abnormalities of the corpus callosum, septum pelucidum and olfactory bulbs.

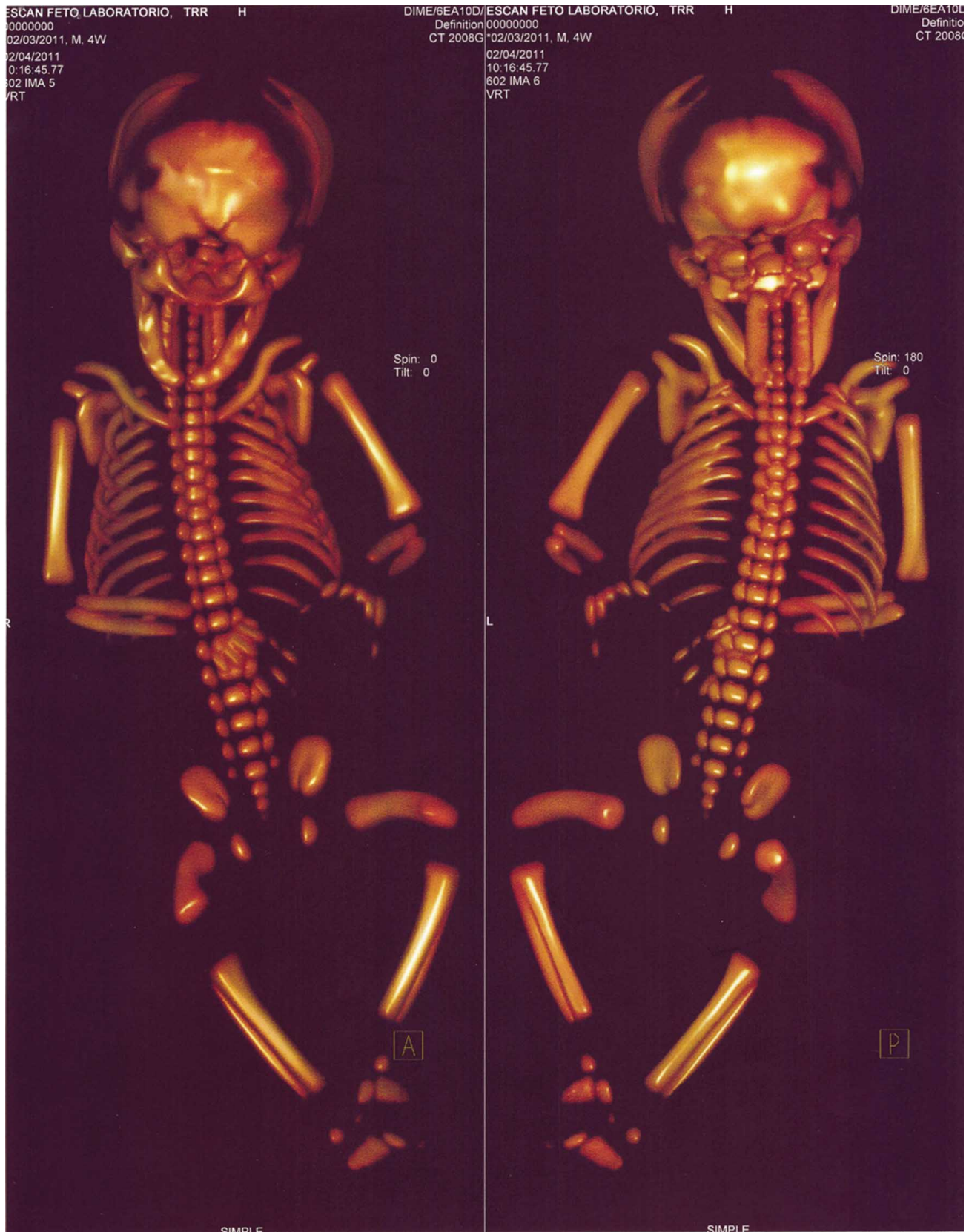


Fig. 3. Multislice computerized tomography with evidence of alobar holoprosencephaly.

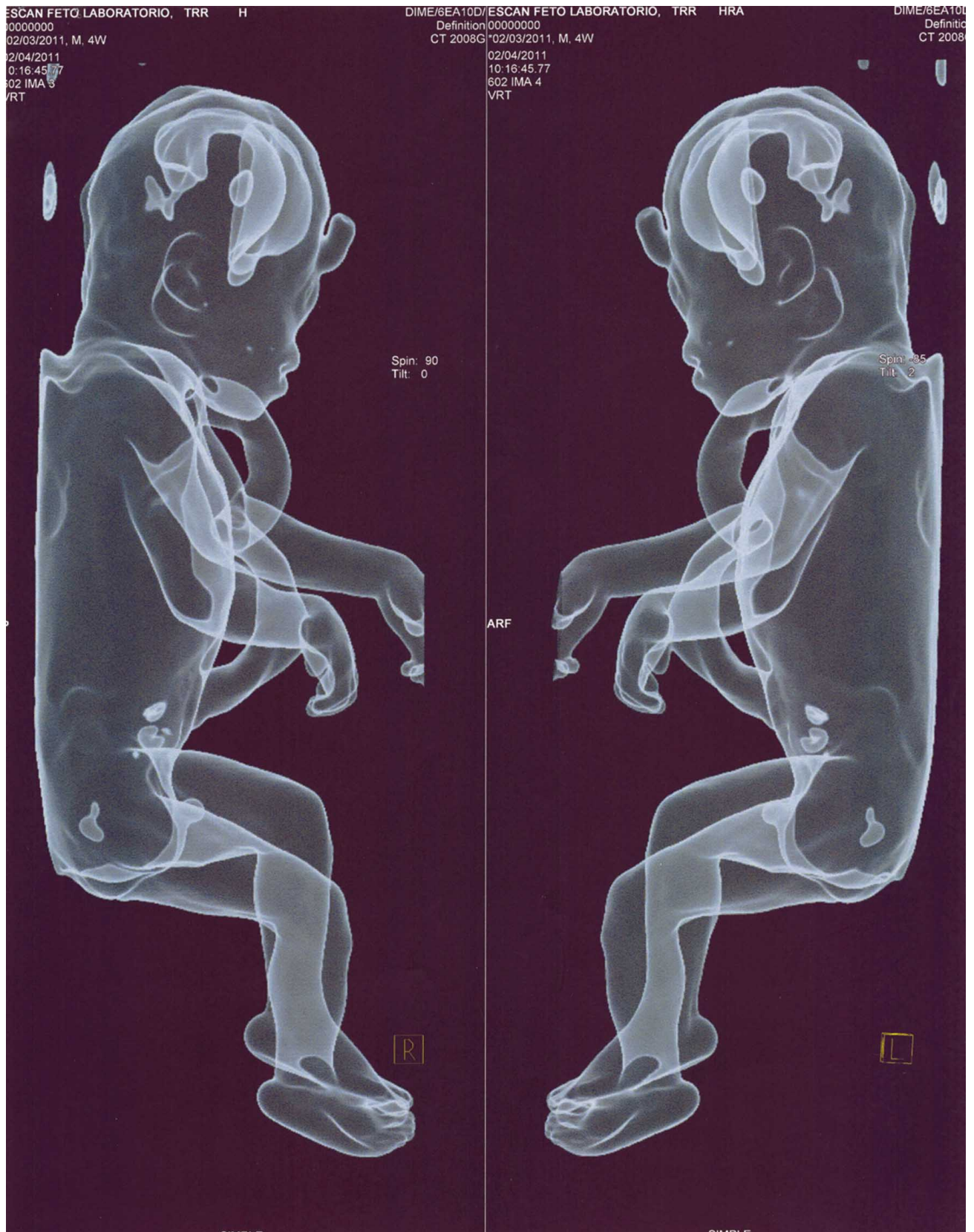


Fig. 4. Multislice computerized tomography with evidence of alobar holoprosencephaly.



Fig. 5. Alobar holoprosencephaly in anatomical post-mortem evaluation.

DISCUSSION

Craniofacial abnormalities most frequently associated with holoprosencephaly are genital abnormalities (24%), postaxial polydactyly (8%), vertebral defects (5%), reduction defects of the limbs (4%) (Orioli & Castilla, 2010), and transposition of the great vessels (4%). Other abnormalities found are synophthalmia (presence of two eyeballs) and microphthalmia (Marcorelles & Shiota, 2010).

The mechanisms of the pathogenesis of cyclopia are unclear, and the etiology of cyclopia is considered heterogeneous because they have linked environmental, teratogenic, chromosomal and monogenic heredity (Cohen & Shiota, 2002). The most important teratogenic factor is diabetes that increases the risk two hundred times; other factors include cytomegalovirus infection, consumption of ethanol and salicylates in the first trimester (Byrne *et al.*, 1987; Martínez-Frías *et al.*, 1998).

A number of genes have been associated with holoprosencephaly and cyclopia, including Sonic Hedgehog (SHH) (Belloni *et al.*, 1996; Chiang *et al.*, 1996) ZIC2 (Brown *et al.*, 2002), SIX3 (Wallis & Muenke, 1999) TGIF (Gripp *et al.*, 2000), and others (Dubourg *et al.*, 2007). Among the chromosomal abnormalities associated with cyclopia, trisomy 13 is the most common (Pachajoa *et al.*, 2008), which was discarded in our patient by conventional karyotype, other abnormalities associated with holoprosencephaly are trisomy 18, triploidy, 7q deletion, and 18p deletion (Thakur *et al.*, 2004; Pachajoa *et al.*, 2007).

The search for the etiology of holoprosencephaly in patients is necessary for genetic counseling, which must include a high resolution karyotype, studies for diabetes, perinatal infections and molecular studies that include mutations for SHH, ZIC2, SIX3 and TGIF (Pachajoa *et al.*, 2010), there were no later studies in our patient. Recently Pineda-Alvarez *et al.* (2010) recommended a genetic algorithm in holoprosencephaly.

3D/4D prenatal ultrasound helps in the prenatal diagnosis of the facial birth defects such as cyclopia, facilitating the acceptance of genetic counseling (Chen *et al.*, 2005). The use of computed tomography may be a good alternative in cases that require morphological analysis and autopsy cannot be done because of lack of consent or because there is no qualified personnel to perform the autopsy.

PACHAJOA, H.; VEJARANO, L. E. & ISAZA, C. Utilización de TAC multicorte 3D en el estudio de un feto con ciclopia.*Int. J. Morphol.*, 30(1):88-93, 2012.

RESUMEN: La ciclopía es una malformación congénita rara e incompatible con la vida, caracterizada por la presencia de un solo ojo en posición central, secundaria a holoprosencefalía alobar. La ciclopía es de etiología heterogénea, con una prevalencia de 1,05 en 100000 nacimientos. Presentamos un caso de ciclopía con sinoftalmía en un feto de 21 semanas en donde se utilizó tomografía computarizada multicorte 3D como estudio complementario.

PALABRAS CLAVE: Ciclopía; Holoprosencefalía; Tomografía; Diagnóstico prenatal.

REFERENCES

- Belloni, E.; Muenke, M.; Roessler, E.; Traverso, G.; Siegel-Bartelt, J.; Frumkin, A.; Mitchell, H., F.; Donis-Keller, H.; Helms, C.; Hing, A., V.; Heng, H., H.; Koop, B.; Martindale, D.; Rommens, J., M.; Tsui, L., C. & Scherer, S., W. Identification of Sonic hedgehog as a candidate gene responsible for holoprosencephaly. *Nat. Genet.*, 14:353-6, 1996.
- Bendavid, C.; Dupé, V.; Rochard, L.; Gicquel, I.; Dubourg, C. & David, V. Holoprosencephaly: An update on Cytogenetic abnormalities. *Am. J. Med. Genet. C Semin. Med. Genet.*, 154C:86-92, 2010.

- Brown, L. Y.; Hodge, S. E.; Johnson, W. G.; Guy, S. G.; Nye, J. S. & Brown, S. Possible association of NTDs with a polyhistidine tract polymorphism in the ZIC2 gene. *Am. J. Med. Genet.*, 108:128-31, 2002.
- Byrne, P. J.; Silver, M. M.; Gilbert, J. M.; Cadera, J. W. & Tanswell, A. K. Cyclopia and congenital cytomegalovirus infection. *Am. J. Med. Genet.*, 28:61-5, 1987.
- Chen, C. P.; Shih, J. C.; Hsu, C. Y.; Chen, C. Y.; Huang, J. K. & Wang, W. Prenatal threedimensional/four dimensional sonographic demonstration of facial dysmorphisms associated with holoprosencephaly. *J. Clin. Ultrasound*, 33:312-8, 2005.
- Chiang, C.; Litingtung, Y.; Lee, E.; Young, K. E.; Corden, J. L.; Westphal, H. & Beachy, P. A. Cyclopia and defective axial patterning in mice lacking Sonic hedgehog gene function. *Nature*, 383:407-13, 1996.
- Cohen, M. M. Jr. & Shiota, K. Teratogenesis of Holoprosencephaly. *Am. J. Med. Genet.*, 109:1-15, 2002.
- Dubourg, C.; Bendavid, C.; Pasquier, L.; Henry, C.; Odent, S. & David, V. Holoprosencephaly. *Orphanet J. Rare Dis.*, 2:8, 2007.
- Gripp, K. W.; Wotton, D.; Edwards, M. C.; Roessler, E.; Ades, L.; Meinecke, P.; Richieri-Costa, A.; Zackai, E. H.; Massagué, J.; Muenke, M. & Elledge, S., J. Mutations in TGIF cause holoprosencephaly and link NODAL signalling to human neural axis determination. *Nat. Genet.*, 25:205-8, 2000.
- Källén, B.; Castilla, E. E.; Lancaster, P. A.; Mutchinick, O.; Knudsen, L. B.; Martínez-Frías, M. L.; Mastroiacovo, P. & Robert, E. The cyclops and the mermaid: an epidemiological study of two types of rare malformation. *J. Med. Genet.*, 29:30-5, 1992.
- Liu, D. P.; Burrotes, D. M. & Qureshi, M. N. Cyclopia: craniofacial appearance on MR and three-dimensional CT. *Am. J. Neuroradiol.*, 18:543-6, 1997.
- Marcorelles, P. & Laquerriere, A. Neuropathology of holoprosencephaly. *Am. J. Med. Genet. C Semin. Med. Genet.*, 154C:109-19, 2010.
- Martínez-Frías M. L.; Bermejo, E.; Rodríguez-Pinilla, E.; Prieto, L. & Frías, J. L. Epidemiological analysis of outcomes of pregnancy in gestational diabetic mothers. *Am. J. Med. Genet.*, 78:140-5, 1998.
- Pachajoa, H.; Saldarriaga, W. & Isaza, C. Síndrome de deleción del 18p por traslocacion balanceada 6p/18p materna asociada a holoprosencefalia alobar. *Rev. Ecuat. Neurol.*, 16:147-50, 2007.
- Pachajoa, H.; Saldarriaga, W.; Tabares, K.; Quintero, J. C. & Isaza, C. Diagnóstico prenatal de ciclopía asociada con trisomía 13. *Colomb. Med.*, 39:80-5, 2008.
- Pachajoa, H. & Isaza, C. Ciclopía con sinoftalmía en un feto de 27 semanas. *Rev. Ecuat. Neurol.*, 19:98-100, 2010.
- Pineda-Alvarez, D. E.; Dubourg, C.; David, V.; Roessler, E. & Muenke, M. Current recommendations for the molecular evaluation of newly diagnosed holoprosencephaly patients. *Am. J. Med. Genet. C Semin. Med. Genet.*, 154C:93-101, 2010.
- Orioli, I. M. & Castilla, E. E. Epidemiology of holoprosencephaly: Prevalence and risk factors. *Am. J. Med. Genet. C Semin. Med. Genet.*, 154C:13-21, 2010.
- Thakur, S.; Singh, R.; Pradhan, M. & Phadke, S., R. Spectrum of holoprosencephaly. *Indian J. Pediatr.*, 71:593-7, 2004.
- Wallis, D. E. & Muenke, M. Molecular mechanisms of holoprosencephaly. *Mol. Genet. Metab.*, 68:126-38, 1999.

Dirección para correspondencia:

Harry Pachajoa, MD, PhD(c)
Calle 18 No. 122-135, Cali
COLOMBIA

Teléfono: 57(2): 5552334 extensión 8032

Email: hmpachajoa@icesi.edu.co

Received: 14-06-2011

Accepted: 02-11-2011